

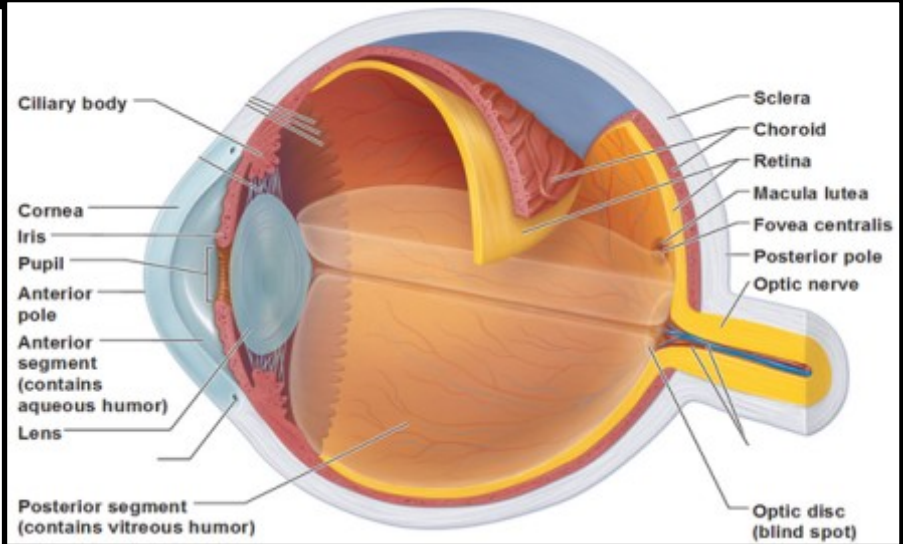
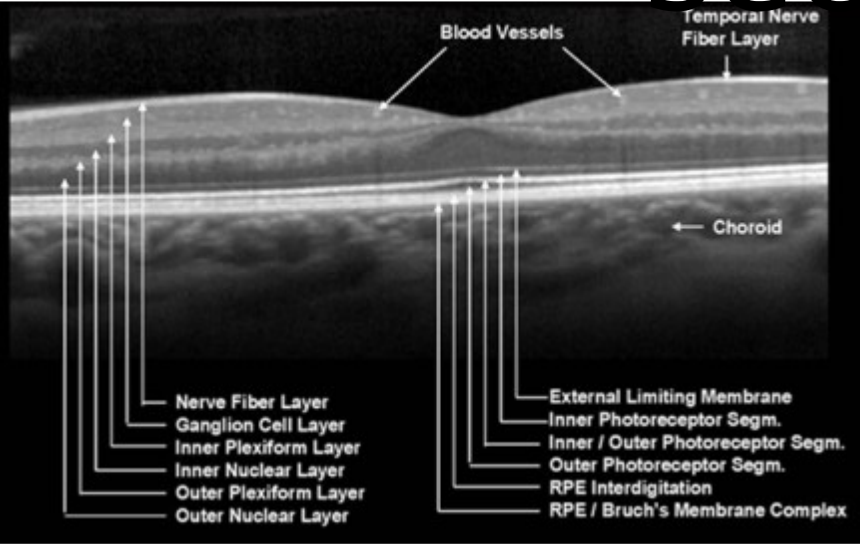


# Your OCT Experience

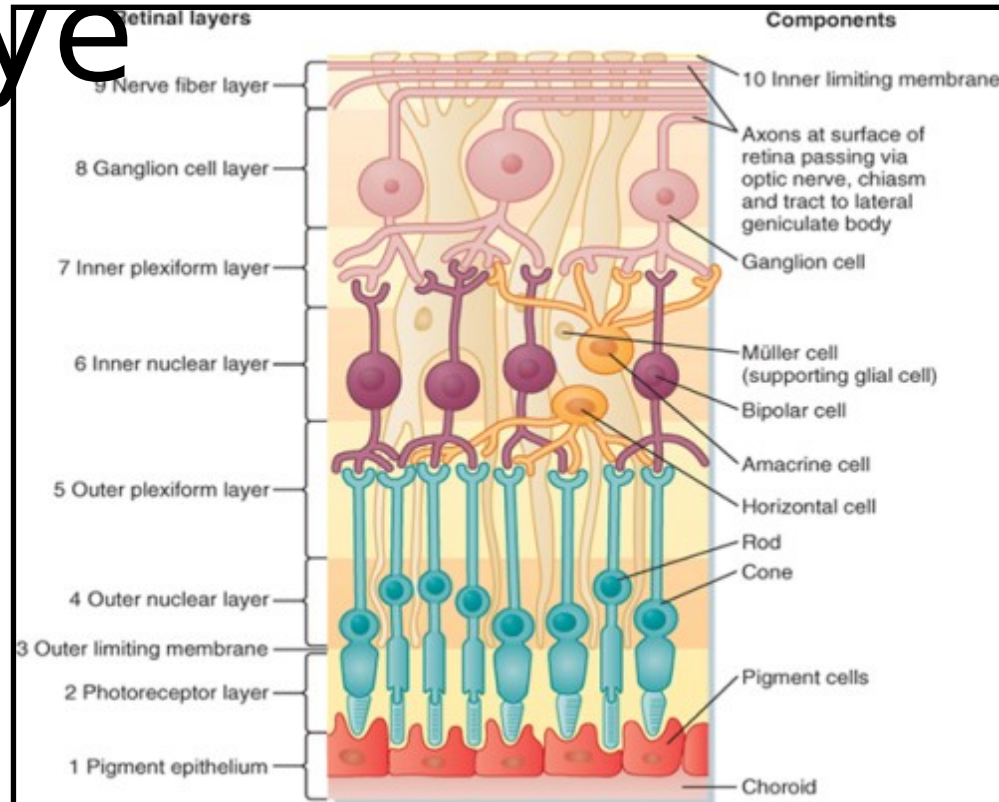
*'Seeing more than before'*




# Retina cross section



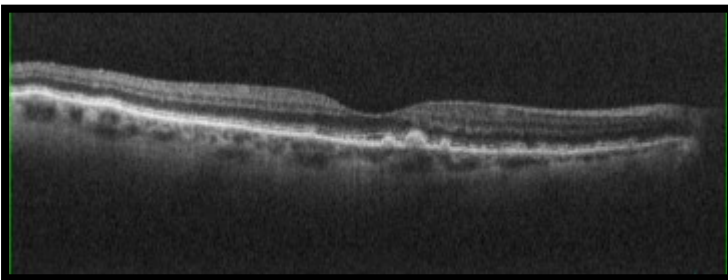
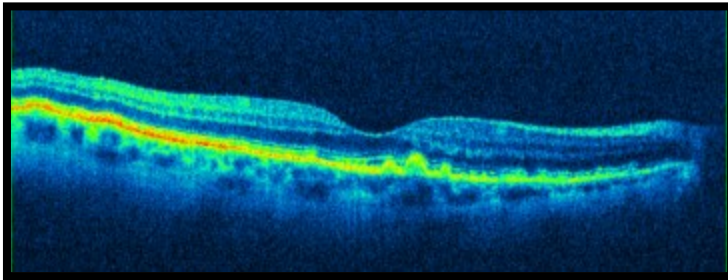
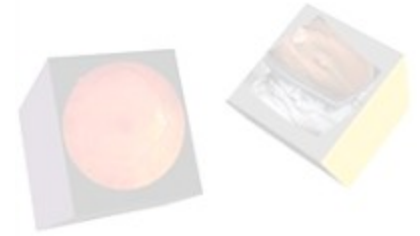# Anatomy of the eye



Did you know  
your **OCT** experience can  
help **detect** many **eye**  
**diseases** ?



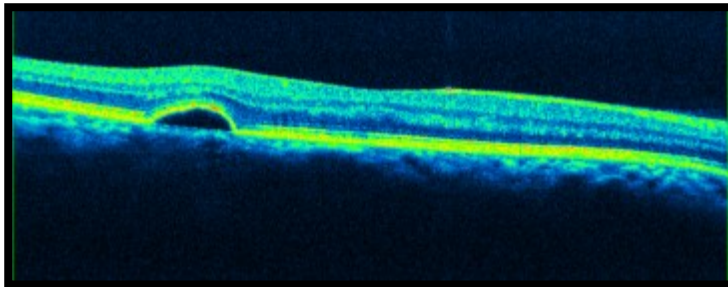
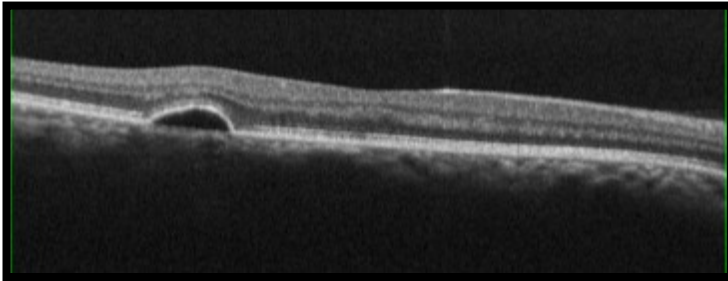
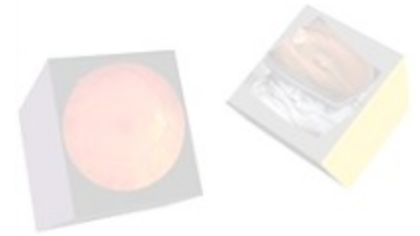# DRUSEN



Always based at the RPE / Bruchs Complex, Drusen cast no shadows. They tend to be of similar reflectivity as the RPE. They show up at the RPE/BM on the En Face scans.



# PED

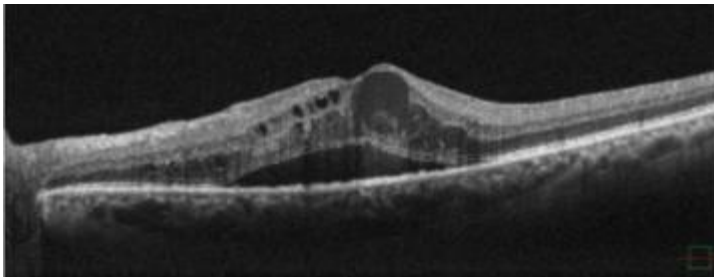
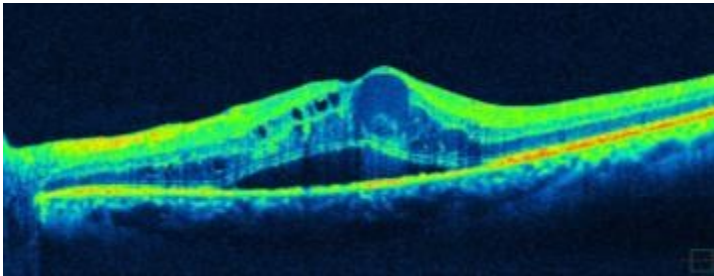


## PED

Pigment Epithelial Detachments occur when serous fluid lifts the whole Retina from Bruch's membrane. If BM is ever visible separately, this is always pathology. Serous fluid is dark (hypo-reflective) and casts no shadow.



# CMO

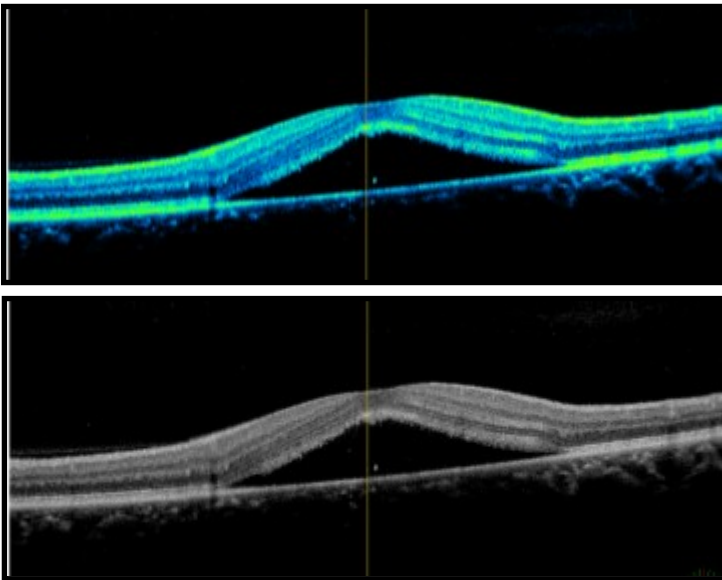


## CMO

Cystoid Macula Oedema shows generally dark serous fluid in cysts that don't cast shadows. Note in this case there is also serous retinopathy present and some haziness from blood plasma in the larger cystic spaces.



# CSR (CSCR)



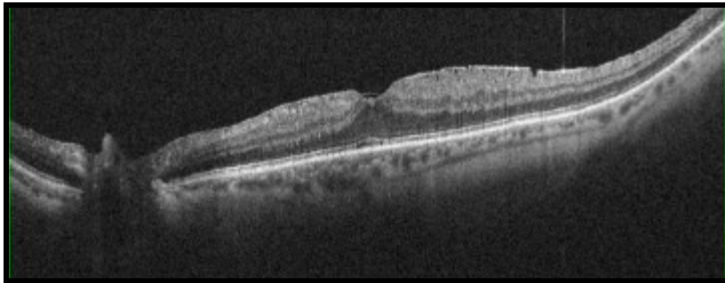
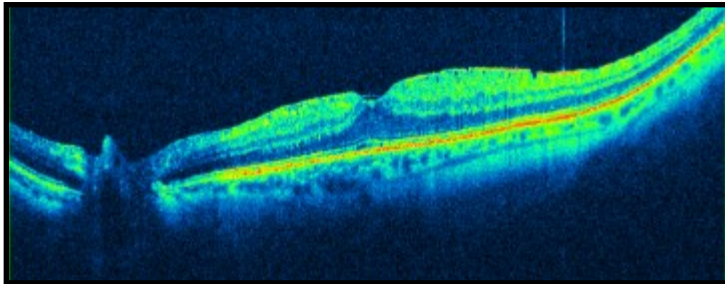
## CSR (CSCR)

Central Serous Retinopathy (Chorio-Retinopathy) classically affects males in their mid thirties roughly. Notice RPE/BM are intact and the neural retina is lifted by serous fluid which casts no shadow.





# ERM

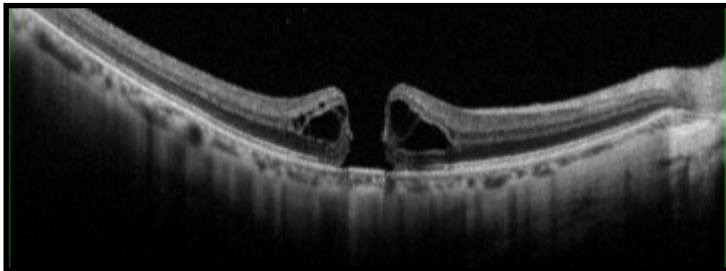
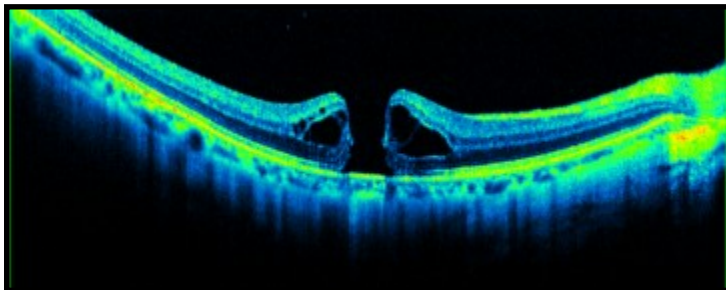
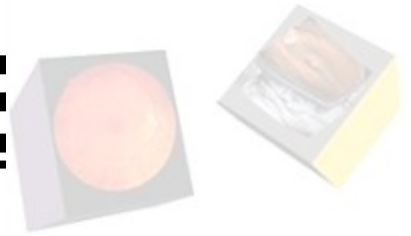

## ERM

Epi Retinal Membranes are extremely common and often don't cause any symptoms. Normally, treatment won't be offered unless the acuity has dropped below 6/24 on average. Traction and Pucker are best viewed with the En Face function.



# MACULA HOLE

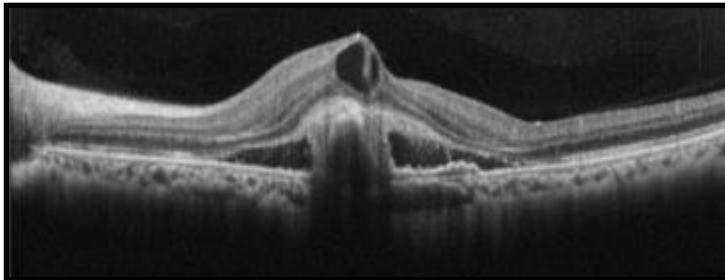
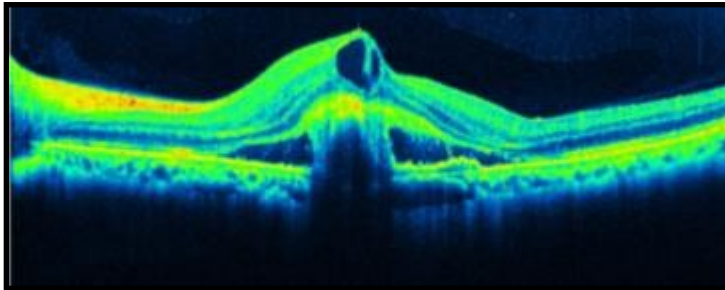


## Macula Hole

This is a full thickness Macula Hole. Note the reverse shadowing at the central Choroid. This sign is often termed the 'Kissing Slugs' and is not to be mistaken with a lamellar hole or Pseudo hole, often caused by an ERM. (Note the Serous Cysts present here).



# WET AMD

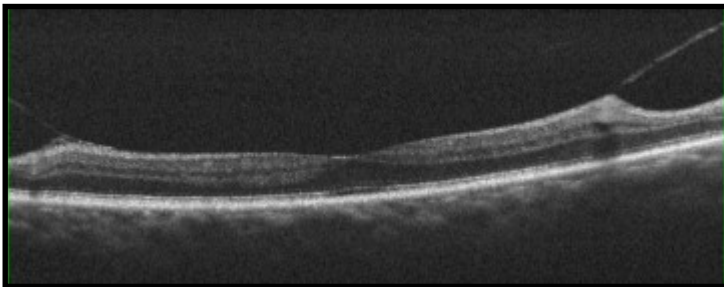
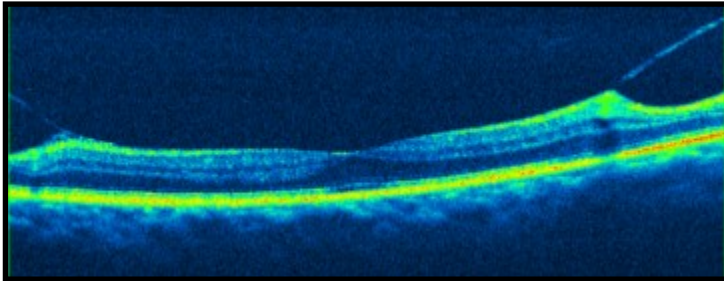


## ERM

Epi Retinal Membranes are extremely common and often don't cause any symptoms. Normally, treatment won't be offered unless the acuity has dropped below 6/24 on average. Traction and Pucker are best viewed with the En Face function.



# VMT

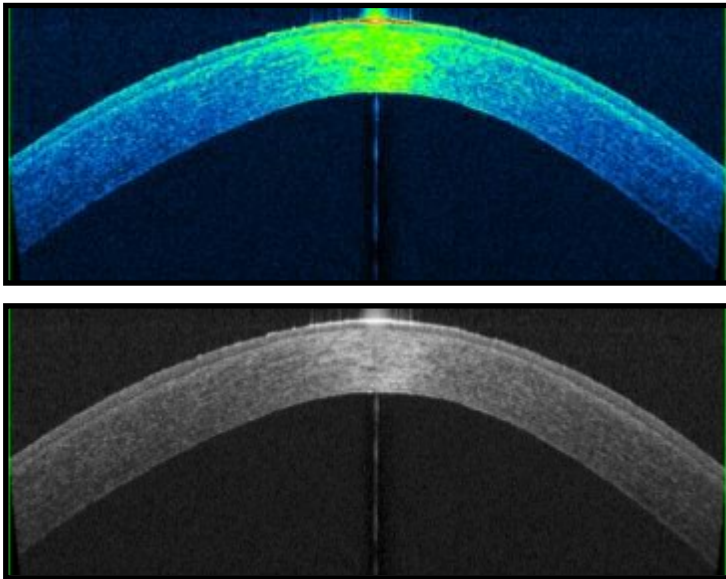
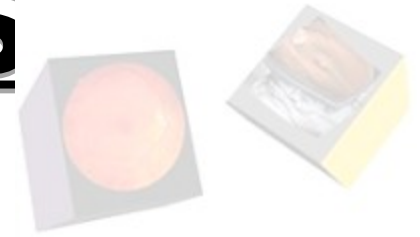

## VMT

Vitreo-Macular Traction can be a precursor to a Posterior Vitreous Detachment (PVD) which is very common. Sometimes, VMT can pull away some of the Foveal pit where the vitreous is loosely attached. A hyper-reflective piece of Foveal tissue may be seen attached to the Vitreal face, known as an Operculum.



# KERATOCONUS (KC)



## Keratoconus (KC)

Here you can make out the Conical cross section of the patients Cornea. It is rare to be able to actually diagnose KC with anterior OCT, but the Pachymetry Maps can also aid with corrected IOPs and the Anterior Chamber Angles can also be measured, for Glaucoma checks.

